



Lasers in the management of snoring and mild sleep apnea

Robert A. Strauss, DDS, MD

*Residency Training Program, Department of Oral and Maxillofacial Surgery,
Virginia Commonwealth University / Medical College of Virginia, Richmond, VA 23298, USA*

In a field that is as complex and confusing as the management of sleep apnea, perhaps no greater controversy has existed over the last few years than the use and efficacy of lasers as a mode of treatment. As with many recent advances in high technology (and especially, when no good low-technology treatment exists), initial enthusiasm and hype, usually propagated by apparent clinical success rather than substantial and objective research, is eventually overtaken by the inevitable complications, lack of the initially seen spectacular results, and the reality that technology is not a replacement for good surgical principles and skill. Eventually, and this is certainly true for the use of lasers in the management of snoring and mild sleep apnea, the practical answer falls somewhere in the middle, indicating that the use of this technology is very much indicated in some cases and contraindicated in others. It is the inherent responsibility of the good practitioner, therefore, to have the data and wisdom to be able to make the clinical judgment differentiating these clinical scenarios. As the pendulum swings back toward its inevitable middle ground based on time and good research, it is becoming more and more evident that lasers have a significant role to play in this disease process, but that role still needs to be better defined.

It must be stated at the outset that, in general, the use of lasers in this disease does not represent a new or unique modality of treatment. Rather, the laser is primarily used as a tool to perform procedures that either have been done in the past, or could be done in the present, with other modalities such as scalpels, electrosurgical cautery, or radio-frequency devices. The indication for using the laser is the practical, and

sometimes theoretical, advantage(s) it represents in any surgical procedure. These include the lack of intraoperative and postoperative bleeding, the ease of access to traditionally difficult areas such as the soft palate and pharynx, the decrease in postoperative pain, and the decrease in scarring.

There are currently two commonly performed laser procedures for snoring and mild sleep apnea: laser-assisted uvulopalatoplasty (LAUP) and laser-assisted uvulopalatopharyngoplasty (LA-UPPP). Though there is some overlap in their techniques and indications, they are two distinctly different surgeries and will, therefore, be described separately.

History

The standard LAUP was originally described by the French surgeon Kamami in 1990 strictly as a means to eradicate simple snoring with a better than 90% success rate, approximately the same as the then-commonplace UPPP [1]. It was adopted in the United States by Krespi in 1992 and rapidly caught on as an office-based alternative to the UPPP [2,3]. The original procedure involved a combination of laser incision within the soft palate and laser vaporization of the uvula. Because the laser used in focused mode as an incision tool is much more effective than the laser used in defocused mode for ablation, the end result was more like a partial uvulectomy than a true palatoplasty. Within a short time, however, the procedure was modified to include laser excision of the uvula and soft palate rather than ablation, thus resulting in a true palatoplasty procedure.

The original procedure was described as a multistep surgery because it was felt that performing the surgery in one step would lead to an unacceptably high rate of

E-mail address: rastrauss@vcu.edu (R.A. Strauss).

velopharyngeal insufficiency (VPI) postoperatively. The surgery was done in small increments, usually requiring 3–5 operations for completion. Although not a major surgery when used for simple snoring, this nevertheless required the patient to take hours off from work several times and, if sedation was used, several days of work, thus negating one of the major advantages of the LAUP over the then-current one-step procedure for snoring, the UPPP. As the procedure became popular and the comfort level of the surgeons increased, it became evident that this fear was unfounded and that, with moderate care in not overextending the boundaries of the surgical excision, the incidence of VPI was remarkably low. Most surgeons soon adopted the concept of a single-stage surgery, with second-stage procedures done only when a treatment failure occurred and it was felt by the surgeon that there was adequate tissue either superiorly, or more commonly laterally, to warrant a second surgery.

In 1994 Kamami published the first article on the use of the LAUP for OSAS [4]. At that time, the procedure performed was identical to the LAUP used for simple snoring. Unfortunately, objective data regarding this procedure was mostly lacking, save for a few early articles [5], and there was justifiable questioning over the use of this surgery [6]. Over the past few years, the procedure has been shown to be safe and effective for socially objectionable snoring, and essentially the same as scalpel UPPP for sleep apnea. Thus, it is fairly effective for mild apnea but is not particularly effective for moderate-severe sleep apnea when used alone, and is therefore only a small part of a much bigger treatment protocol necessary for the treatment of significant sleep apnea.

Recently, many surgeons have changed their technique from a LAUP to a LA-UUP, essentially performing a UPPP with a laser instead of a scalpel. This provides similar results but with the bloodless, lower morbidity and more controllable advantages of laser surgery. Most surgeons who use this procedure in the management of sleep apnea do so in combination with other procedures that also are not usually effective by themselves such as genial advancement, hyoid myotomy and suspension, or nasal surgery. In combination with these procedures, the LA-UPPP, like the scalpel UPPP, can be an effective therapeutic tool.

Preoperative evaluation

Prior to performing surgery on the airway in any patient, a proven or presumptive diagnosis should be established. It is imperative to differentiate the patient with simple snoring from those with mild sleep apnea,

moderate sleep apnea, and severe sleep apnea. Although these diseases probably represent more of a continuum than separate entities, their management is usually quite different. It is also important to know whether apneic events are obstructive or central in nature, and the severity of any cardiac or hypoxic events. Finally, it is useful to attempt determining the possible anatomical causes of any airway obstruction and rule out pathologic lesions within the airway.

For the patient with known or suspected sleep apnea, the workup is relatively straightforward and includes a thorough physical examination with particular emphasis on the upper airway, a cephalometric radiograph, thyroid function studies, and a polysomnogram. Additional targeted laboratory and radiographic studies may be ordered where appropriate. Any patient undergoing surgery of the upper airway for sleep apnea should also have a preoperative nasopharyngoscopy to rule out pathologic entities that may be causing the obstruction as well as to determine the likely sources of the obstruction, thus enabling the surgeon to choose the correct procedure for that patient [7,8]. Diagnostic maneuvers such as Mueller's maneuver can be beneficial in this diagnostic process. The diagnosis and workup of sleep apnea patients is covered extensively elsewhere in this issue and will not be repeated here.

More controversial is the appropriate workup for the patient with suspected simple snoring. This is the patient who presents with the singular complaint of snoring, and without associated complaints of daytime somnolence, or cardiac, neurologic, or respiratory signs and symptoms consistent with sleep apnea (or with minimal symptoms consistent with very mild sleep apnea). Though a laboratory polysomnogram would be an ideal method to rule out obstructive sleep apnea, this is an expensive test that requires the patient to be away from home and is often refused by insurance companies as being an unnecessary test in the absence of the signs or symptoms. Nevertheless, it is incumbent on the prudent practitioner to rule out sleep apnea (which requires a different treatment regimen than snoring) in a more objective and reliable way other than just history, which can be incorrect in up to 30% of cases. One reasonable alternative is the use of home polysomnography. A number of commercial, multichannel home recorders are available that enable the patient to take the device home, apply it during sleep, return it to the practitioner who can either read and analyze the information on their own computer, or download the information to a technician remotely who can read the study and relay the information to the practitioner. Another alternative is a home device that measures airway sounds and

provides interpretive data indicating the presence and severity of sleep apnea. Although these devices fail to provide electroencephalographic data to indicate the stages of sleep, they have been shown in objective studies to correlate well with the final results of full laboratory polysomnograms [9–11]. They also have the advantage of their portability, ease of use, and extremely low cost of use. Once the diagnosis has been confirmed, the practitioner can choose the procedure of choice he or she feels appropriate for that particular patient.

Technique

Laser-assisted uvulopalatoplasty

After appropriate diagnostic workup of the patient indicating simple snoring or mild sleep apnea not requiring other therapeutic measures, the choice of a LAUP may be made as an appropriate procedure. The procedure is most commonly performed in the office environment and may be conducted using local anesthesia only, or light to moderate I.V. sedation. Deep sedation and general anesthesia are rarely necessary and make the procedure more difficult, and in the case of a sleep apneic patient, more dangerous because of potential airway difficulties. It should be remembered that all of these patients have anatomically compromised airways, and intubation is often difficult, leading to a significant rate of morbidity and mortality.

After thorough informed consent, the patient is seated in a dental chair in the sitting position. This is the easiest position for the surgeon as it allows the soft palate to drape as far anteriorly as possible, providing the greatest space for the backstop hand piece, keeping the palate off the posterior pharyngeal wall, and minimizing the risk of inadvertent conductive thermal damage. It also decreases the incidence of gagging. Although the surgery can be done in the supine or semisupine position (as would likely be needed for general anesthesia), it is considerably more difficult.

Prior to instillation of the local anesthetic or I.V. sedation, the insertion of the levator veli palatini muscle must be identified. This can be accomplished by having the patient phonate while looking for the point of vertical traction of the soft palate. In those rare patients where this is difficult to determine, a cotton swab can be used on the pharyngeal wall to briefly gag the patient. This will exaggerate the insertion and almost always make it easily visible. During surgery, the patient can be asked to repeat this maneuver as needed to confirm its location (another advantage of local anesthesia or light sedation over

general anesthesia). In all cases where general anesthesia is used, and in some cases where local anesthesia is used, it is helpful to mark this location preoperatively with an indelible marker such as a blue denture-marking stick. It is of utmost importance during the procedure not to violate this insertion, as velopharyngeal insufficiency can result, leading to hypernasal speech and/or nasal regurgitation of fluids after drinking. Although this is not an uncommon temporary annoyance postoperatively (for 1–3 weeks), when it occurs long-term it is a major morbidity with significant consequences for the patient.

Should I.V. sedation be desired, it is performed in the routine fashion using a benzodiazepine (either diazepam or midazolam) and a short-acting narcotic (eg, fentanyl). Small doses of methohexital or propofol may be used as needed, but it should be remembered that the patient needs to be kept in a light plane of sedation and the dosages adjusted accordingly. The use of supplemental oxygen during the procedure is somewhat controversial. Though no cases have been reported to date of an airway fire during LAUP or LAUPPP, the potential of oxygen to support combustion makes its use during surgery somewhat worrisome at least. There are two techniques that may be used. Of course, the oxygen can be turned off during the actual laser and replaced only if the pulse oximeter indicates that the patient is getting hypoxic. Alternatively, the oxygen can be given by nasal cannula with the nose draped off from the surgical site. The admixture of the oxygen and room air that reaches the pharynx makes significant combustion unlikely. Keeping the sedation light minimizes the chance of ventilatory depression and the subsequent need for oxygen supplementation.

Local anesthesia in this region is remarkably effective and surprisingly uncomplicated. The tongue is retracted with a butterfly tongue retractor. A dental syringe of lidocaine 2% with 1:100K epinephrine and a 1.5 inch, 25–27 gauge needle is used to inject in five places: the midline of the soft palate about 1 cm above the base of the uvula, just lateral to the uvula adjacent to the midline injection bilaterally, and above the tonsillar pillars bilaterally. A total of approximately 1.5–2.0 cc is injected to limit the amount of fluid in the tissues, prevent distortion of the anatomy, and avert excessive absorption of the CO₂ laser and the need for high fluences (the total energy necessary) with resultant lateral thermal spread. If needed or desired, a small additional amount may be comfortably injected after the patient has been anesthetized from the initial dose. Rarely will more than 3 cc be necessary for the entire procedure. Some practitioners prefer to use bupivacaine before or after surgery to

lessen short-term postoperative discomfort. Finally, some surgeons will inject a small dose of steroids (eg, dexamethasone 4–6 mg) directly into the surgical site whereas others provide the dose I.V. to limit swelling and discomfort. It is the experience of the author that the use of systemic steroids does indeed decrease the morbidity of the postoperative course.

In order to prevent inadvertent thermal damage to the posterior pharyngeal wall, the use of a backstop hand piece is highly desirable (although a nonbackstop hand piece and a separate protector behind the soft palate will also work). As with all laser procedures, it is imperative for the surgeon to understand completely the physics involved in order to maximize the advantages of the laser while minimizing collateral thermal conductive damage. The basic concept that adjacent tissue damage is primarily related to the time duration of laser exposure is an important tenet in laser surgery. Therefore, it is the goal of the surgeon to perform the surgery with the least time on tissue as possible [12]. That is, the fluence should be applied in the shortest period of time possible (fluence rate) while still being able to maintain control of the laser. This translates into using fairly high power and power densities (generally 15–18 watts

with a 0.1–0.8 mm spot size depending on the specific laser used) in a series of rapid, short continuous bursts of laser use. This technique also limits heating of the backstop with secondary conduction into the pharyngeal wall. A good rule of thumb is to use the laser continuously for no more than 5 seconds before testing the temperature on a gloved finger. If the backstop is particularly hot to the touch, it should be allowed to cool down before continuing.

Patient and operator safety during the procedure is of paramount importance. Because of the large amount of laser plume generated during this procedure, the use of a smoke evacuator with a biologic filter is highly recommended. In addition, specific face masks designed for laser surgery and using a small pore size to capture laser plume particles are commercially available. Everyone in the operatory, including the patient, should have appropriate eye protection as well.

Once anesthesia is established, the tongue is retracted again with a butterfly retractor. This can be done by the surgeon, the assistant, or even by the patient. A useful trick to remember is that the patient will often be able to retract further back on the tongue without gagging than if the surgeon or the assistant

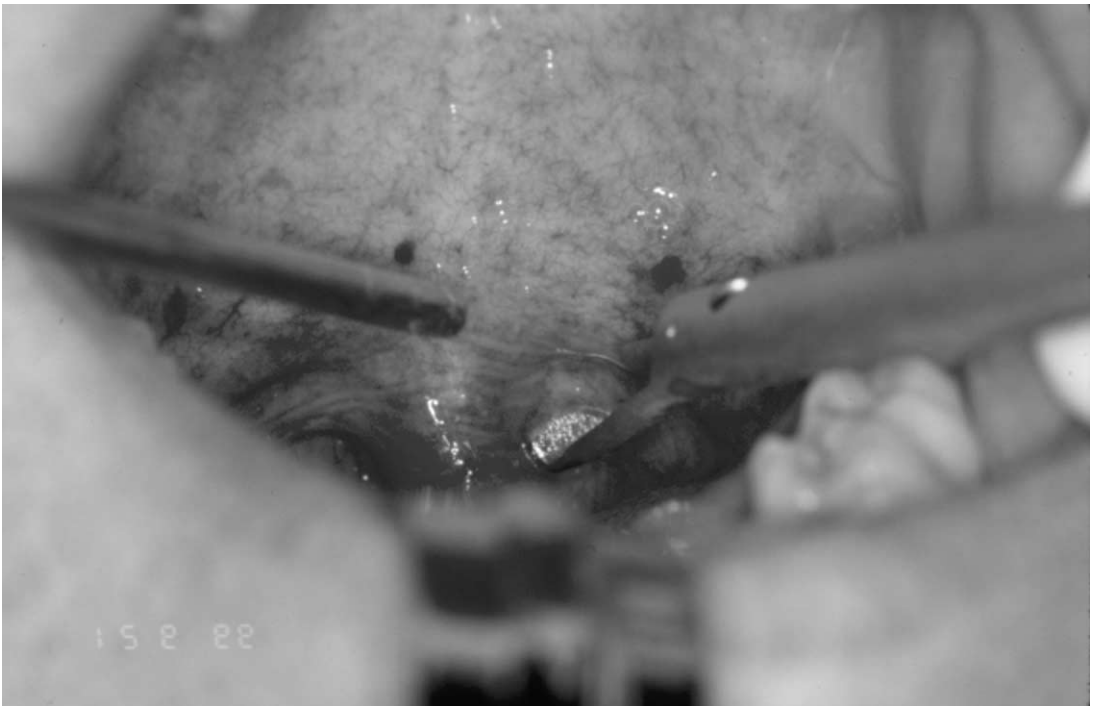


Fig. 1. The laser placed just lateral to the uvula for the vertical trenches. The backstop hand piece is used to protect the pharyngeal wall from damage.

does this. With a small amount of coaching, the patient should be able to use the hand opposite to the side the surgeon is on to enable adequate visualization of the surgical site without interfering with the surgeon's access and line of vision. The backstop is then placed behind the soft palate, and the procedure begun.

Although originally done essentially as a uvulectomy, and performed sequentially in 3–5 sessions [1], the procedure has evolved into a much more aggressive resection of the soft palate and tonsillar pillars as well as the uvula, and is done in a single session in most cases. The surgery is essentially comprised of three steps. Initially, the backstop is placed in the junction of the uvula and soft palate on one side and a vertical cut, also called a trench, is made through-and-through the soft palate (Fig. 1). This is done, as mentioned earlier, using high-power density in incisional laser mode (ie, at or near the focal point of the laser). It is extremely beneficial to use a suction tip or bayonet forceps to traction toward the contralateral side during the incision. Vertically, this is taken to approximately 3–4 mm below the insertion of the levator veli palatini muscle as described earlier (and which can be found by phonation or via the previ-

ously made indelible mark). Generally, this translates into a vertical cut of about 1.5–2 cm. Great care must be taken not to violate this insertion. This procedure is then performed in an identical fashion on the contralateral side (Fig. 2).

The second step is excision of the uvula and soft palate superiorly defined by the two previously made vertical trenches. The backstop is placed at the top of one of the trenches and turned medially. A horizontal cut is then made, in a continuous focused mode, to connect the tops of the trenches (Fig. 3). This can be facilitated by cutting from either side and meeting in the middle, rather than going from one side to the other, and also by again grasping the uvula with a long forceps, as the use of counter traction greatly enhances the cutting ability of the laser. The specimen is then removed and may be submitted for histological examination if desired.

Once the central area of the soft palate is removed, one can often find the lateral palate and tonsillar pillars to be still constricting the airway. In the third and final step, the laser can then be used in either a focused or defocused manner to excise or ablate these tissues superiorly to inferiorly (Fig. 4). Generally, this is done

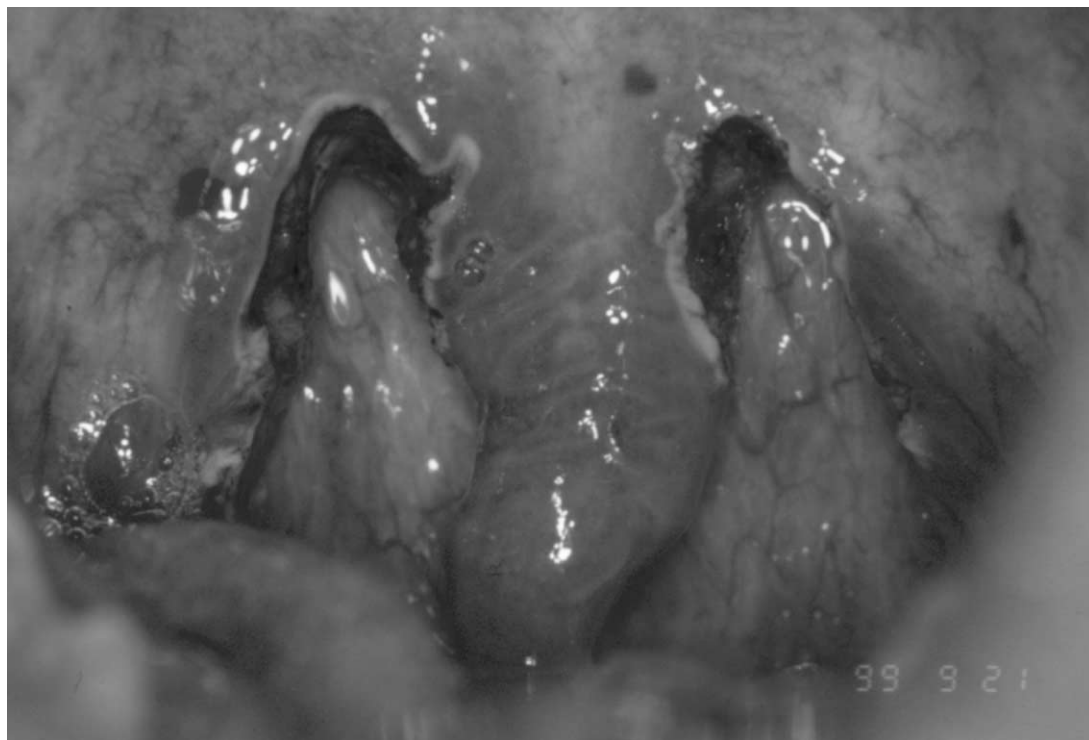


Fig. 2. The bilateral vertical trenches stopping just short of the levator muscle insertion.

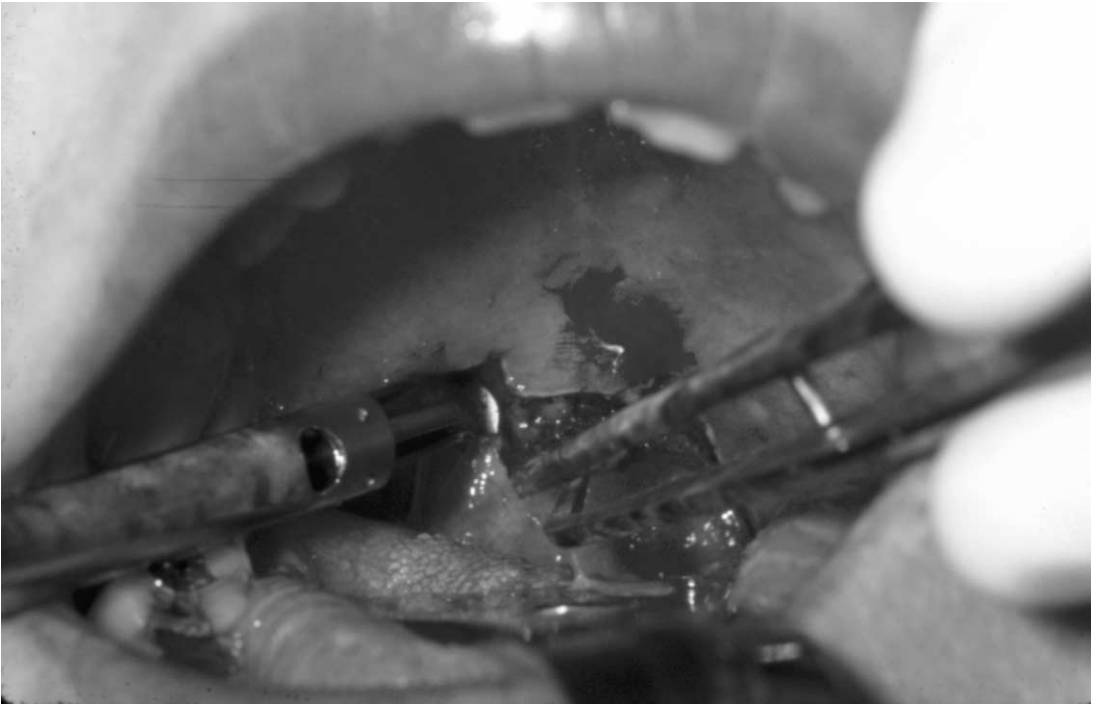


Fig. 3. The backstop is turned sideways to allow for excision of the uvula and soft palate at the top of the vertical trenches. Counter traction is gently applied to the uvula with a forceps or suction.

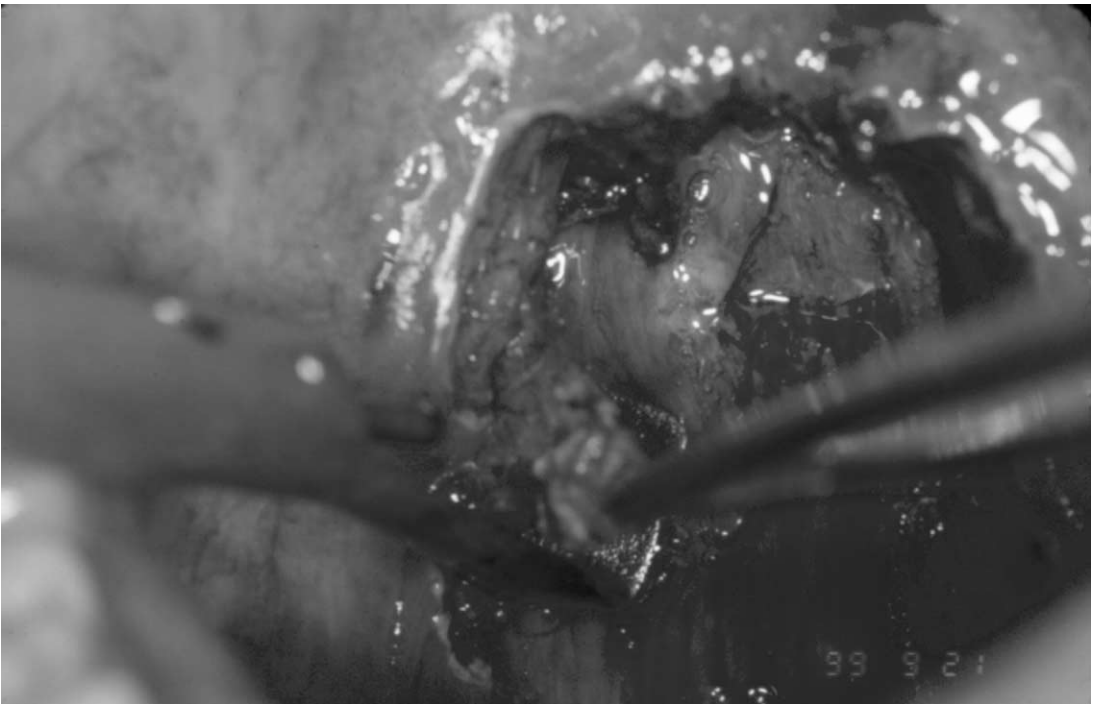


Fig. 4. The tonsillar pillar tissues can be excised or ablated to increase the airway opening laterally.

for 3–5 mm laterally to minimize postoperative bleeding and pain. Although the surgeon may choose otherwise (some surgeons believe this increases the success of the procedure and decreases postoperative pain), suturing is not necessary for healing. In the unlikely event of mild bleeding, the laser may be used for hemostasis if the vessel is 500 microns or smaller. For vessels that do not respond to the laser but are too small to warrant ligation or the use of an electrocautery, a silver nitrate stick may be very helpful.

At the conclusion of the procedure, the patient is asked to phonate and drink a small amount of fluid to verify velopharyngeal competency, although the anesthetic may make this exam less than realistic. The patient may return to work, school, or home at his or her discretion and predicated on the type of anesthesia used.

Uvulopalatopharyngoplasty: laser-assisted (LA-UPPP)

When the diagnosis of sleep apnea (rather than simple snoring) has been made, it is generally accepted that the standard LAUP procedure is not an ideal procedure for cure by itself. Toward this end, the relative efficacies of various laser procedures will be discussed later in this article. One recent alternative, the LA-UPPP, is being used by some surgeons in the management of sleep apnea. Essentially, it is a variation of the traditional UPPP procedure that takes advantage of the strengths of the laser.

Because this is a relatively new variation, there is some variability in the manner in which this procedure is performed; however, the basic concept is very similar to that of a standard UPPP in that there is not only removal of the soft palate and uvula, but also excision of both the anterior and posterior tonsillar pillars. In addition, there is some undermining into the lateral pharyngeal tissues, and suturing is done to maximize the airway dilation and prevent relapse. It should be noted that this procedure only works when the patient has either previously undergone tonsillectomy or has small residual tonsils. In this case, the tonsils can be ablated to a depth of a few millimeters as part of the procedure. Large tonsils should either be removed prior to the procedure, or a standard UPPP performed.

The LA-UPPP can be done with the same local anesthetic injections used for a standard LAUP. Because many of the patients receiving this surgery are sleep apneics, however, they will often be simultaneously undergoing other surgical procedures, such as genial tubercle advancement and hyoid myotomy

(GAHM) or nasal surgery. As such, they may require an operating room and general anesthesia. It is also strongly recommended that consideration be given to having these patients admitted for overnight observation because of the greater potential of postoperative airway compromise. In severe cases, or in smaller community hospitals, a monitored bed may be appropriate. The patient is prepped and situated in the same fashion as for a standard LAUP. Once again, the procedure is easier to do in the sitting position, although when done in the OR the supine position may be necessary and is not a problem as long as the levator muscle is marked preoperatively.

The initial vertical trenches are the same as in the LAUP, although they are taken as far laterally as can be done comfortably within the soft palate to include some of the anterior and posterior tonsillar pillars. Again, this can be aided by grasping the uvula with a forceps, hemostat, or suction tip, and applying counter traction during the laser incisions. A horizontal incision can then be made across the top of the vertical trenches to remove the uvula, soft palate, and some of the medial aspect of the tonsillar pillars. Additional ablation or excision of the pillars can be carried out until the operator is sure that the airway has been maximized. At this point, the soft palate is grasped with a long forceps, rotated anteriorly so that the long aspect of the palate is facing into the mouth, and a nonbackstop hand piece is used to remove a triangular wedge of tissue from the soft palate between the anterior and posterior palatal mucosa but still leaving 3–4 mm to the levator insertion (Fig. 5). This essentially undermines the soft palate and allows for significant thinning.

At the conclusion of lasering, there should be an anterior mucosal flap comprised of the oral mucosa of the palate and the anterior tonsillar pillar, and a posterior mucosal flap comprised of the nasal side of the palatal mucosa and the posterior tonsillar pillars. All of the flap edges should, and indeed must be, de-epithelialized. At this point the posterior flap is stretched anteriorly and brought into apposition with the anterior flap, overlapping it for 1–2 mm. A series of 4-0 polyglactin or polyglycolic sutures are then used to coapt the two flaps (Fig. 6). The resultant suture line is essentially identical to that seen with a standard UPPP (Fig. 7).

Advantages of this procedure over standard UPPP include considerably less bleeding and slightly less postoperative discomfort. In addition, the procedure is faster and, when appropriate (for nonapneics), may be performed on an outpatient basis or even in the office. The relative efficacy of these procedures will be discussed later in this article.

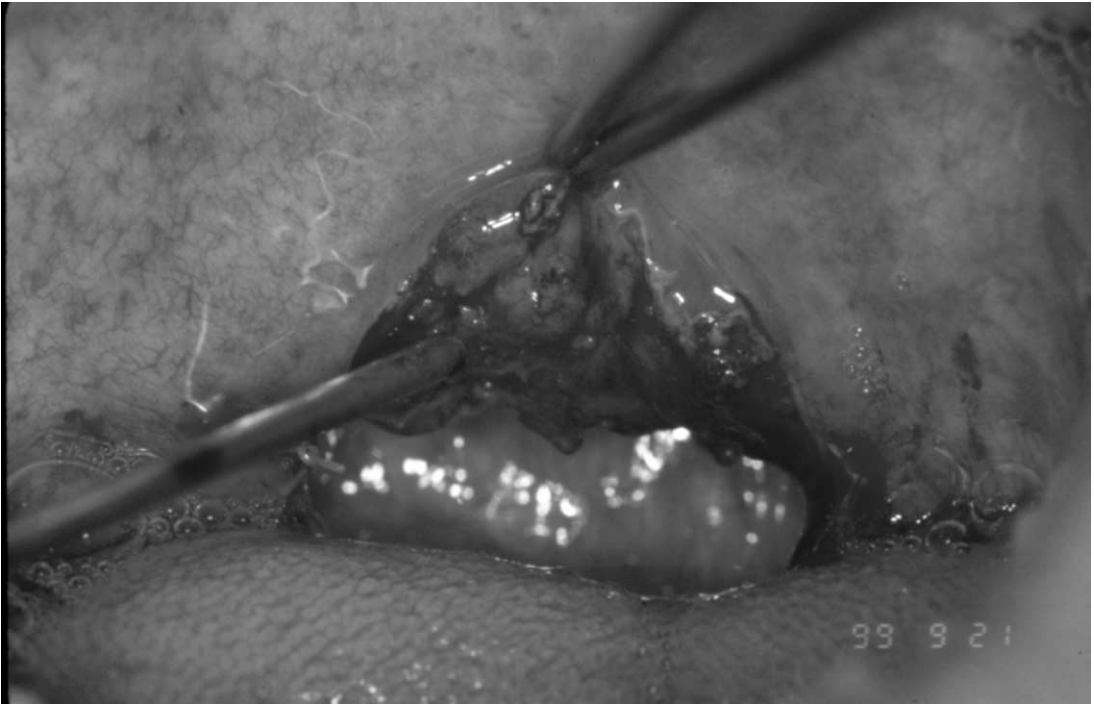

Fig. 5. The soft palate is rotated anteriorly, and a wedge of tissue removed with a nonbackstop hand piece to allow thinning of the soft palate and soft tissue closure.

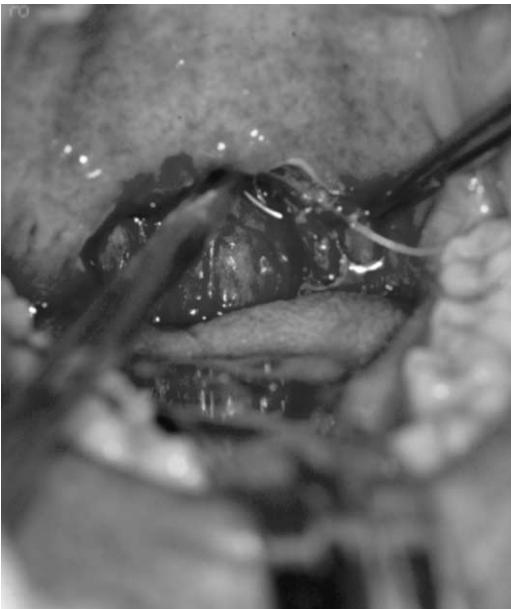


Fig. 6. The posterior tissues are stretched forward and sutured to the anterior tissues. This helps to further open the airway and affect pharyngeal wall tightening.

Postoperative care and instructions

The postoperative care for both of these procedures is much the same. The patient is instructed to return to work as soon as he or she feels ready after discharge from the office or hospital, usually within 1–2 days if sedation or general anesthesia has been used, and immediately postoperatively if local anesthesia has been used. Although the inevitable sore throat lasts 8–10 days, patients often do better when back in their normal routine rather than focusing on their pain.

Prescriptions are given for short-term systemic steroids (a dosepak is useful but expensive) and a moderate analgesic such as acetaminophen elixir with codeine. Stronger analgesics should be avoided as they increase the risk of respiratory depression, apneic events, and airway compromise. If preferred, a long-acting local anesthetic such as bupivacaine may be used in place of the lidocaine for initial anesthesia or at the end of the procedure to provide several hours of comfort. The routine use of antibiotics is not necessary because, as with most intraoral surgeries, infections are very rare, and when they do occur they are likely to be candidal.

Along with warm saline rinses, topical anesthetic lozenges, sprays, or viscous liquids are very helpful

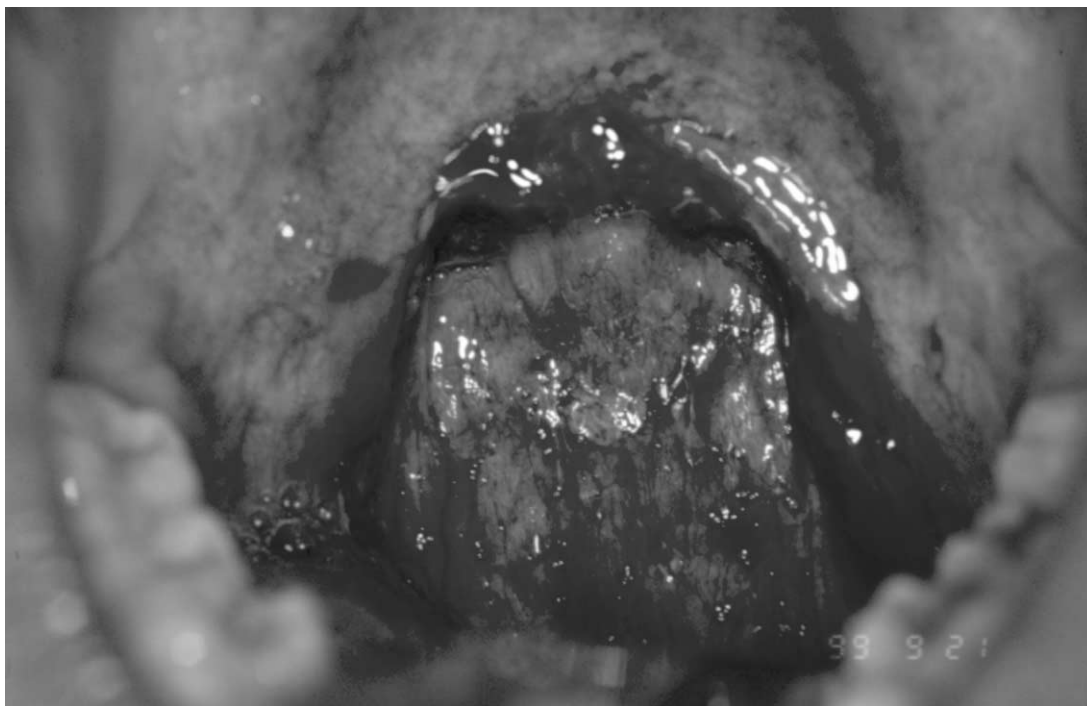


Fig. 7. After completion of the LA-UPPP, showing significant opening of the airway.

in controlling the discomfort between the systemic agent doses. A soft, nonthermal diet is also important, as anything excessively hot or cold will cause increased pain. In general, postoperative pain is related primarily to swallowing and when at rest the patient is often nearly pain-free. A bedside humidifier can provide a moist environment at night to prevent drying out of the airway. Sleeping in an upright or semi-Fowlers position is encouraged and the patient should have someone else nearby during sleep for the first 48 hours in the unlikely event of an airway compromise. If the patient was using continuous positive airway pressure (CPAP) before the surgery, it should be continued as soon as it can be worn comfortably after surgery. Usually this is 5–7 days postoperatively, but in some cases it can be as long as a few weeks until this can be accomplished.

Complications

Although the LAUP and LA-UPPP procedures are usually benign and effective surgeries, there still exists the potential for serious, and occasionally catastrophic, events. Careful diagnosis, treatment planning, and postoperative care can, however, diminish the chances of these complications significantly.

Intraoperatively, the main complication that occurs is bleeding. This usually occurs at the base of the uvula from the small artery that supplies this area. Treatment involves the use of a silver nitrate stick but, if severe enough, may require electrocautery or even a ligature suture. Another intraoperative complication is gagging. This occurs not from action on the soft palate, but rather from depression of the tongue for visibility. This can be limited by minimally retracting the tongue or by having the patient hold down their own tongue, which not only decreases the gagging but also often results in improved retraction. If severe, nitrous oxide can be of benefit, and light I.V. sedation with a small amount of a benzodiazepine will usually eradicate gagging altogether.

Postoperative complications include bleeding, velopharyngeal insufficiency, airway compromise, infection, and scarring. Postoperative bleeding may occur when a cut vessel, diminished by the vasoconstrictor, suddenly dilates as the local anesthetic wears off. This is treated in the same manner as bleeding that occurs intraoperatively. Velopharyngeal insufficiency results from inadvertent impingement on the levator palatinus insertion in the soft palate. It is manifested by hypernasal speech and nasal reflux, which may range from mild (eg, nasal reflux when bending over) to complete incompetency [13–15].

Some mild insufficiency is not uncommon after any palatal surgery but usually disappears within a few weeks of the surgery. The incidence of this complication after traditional UPPP ranges from 1–13% but should be lower for LAUP and LA-UPPP because they are often performed under local anesthesia and this allows constant visualization and identification of the levator position.

Airway compromise is, fortunately, rare after UPPP, LAUP, or LA-UPPP. Nevertheless, case reports of severe bleeding and airway compromise requiring emergency cricothyrotomy or tracheostomy have been reported [13–15]. Patients at risk for airway compromise (eg, patients with severe sleep apnea) should be operated on in a controlled environment and should be placed in a monitored hospital bed postoperatively. Patients with simple snoring and mild sleep apnea are commonly operated on quite safely in an office environment and discharged home postoperatively. Even with a standard LAUP for simple snoring, however, studies have shown that in the immediate postoperative period there can be a net decrease in airway size of as much as 4% [16]. Therefore, judicial observation of any patient at perceived risk is warranted.

Infections following soft palate surgery are fortunately quite rare, owing to the excellent blood supply of this region. A few cases of oral candidiasis have been reported, undoubtedly caused by the use of antibiotics to prevent bacterial infections [17]. It is the opinion of many surgeons (including this author), that the routine use of antibiotics after surgery is not indicated for this reason.

Scarring after laser-assisted palatal surgery can occur either in the soft palate/tonsillar pillar complex or in the pharyngeal wall. Soft palate scarring occurs through the natural process of tissue damage, collagen formation and contraction of the wound. It is usually mild and expected, causing no significant airway constriction or functional problems. Rarely, it can lead to velopharyngeal insufficiency, pain, and some measure of airway diminishment. Scarring of the pharyngeal wall is always caused by inadvertent conducted thermal damage from the backstop hand piece. Although the handpiece is designed to prevent direct laser damage to the pharynx, the backstop itself can be heated by thermal conduction from the lasered tissue, which in turn is then conducted to the pharyngeal wall if touched. It is seen most commonly when the soft palate and pharyngeal wall are in close proximity. This can be easily prevented if the laser is used in short bursts of less than 5–10 seconds at a time, if the backstop is kept off the pharyngeal wall, and if the surgeon intermittently checks the backstop

for elevated temperatures. In its worst form, the thermally damaged pharyngeal wall can attach to the denuded surface of the operated soft palate and cause a devastating total or near-total oronasal separation. (Fig. 8).

Speech problems following surgery have mostly been related to hypernasal speech secondary to involvement of the levator palatinus muscle. Although it does not seem to be a significant complication, it is at least theoretically possible that normal speech sounds could be affected by any palatal surgery. This would be especially true for patients who speak languages requiring guttural or trill sounds or who sing a great deal. Because of this it is wise of the surgeon to warn the patient of this possibility prior to surgery and include this in the informed consent process.

Finally, many patients who undergo these procedures complain of an abnormal sensation in the back of their throats. It occurs at a rate of approximately 30% of all patients and lasts up to 1 year postoperatively. This sensation, called globus, is not associated with any particular anatomical abnormality and is not a functional problem [18]. It is, however, quite perturbing to a large number of patients. Hence, it is incumbent on the surgeon to warn the patient of this and provide support and reassurance when the patient complains of this after surgery.

In summary, it would appear that the LAUP and LA-UPPP, when performed judiciously on selected patients, are relatively safe procedures associated with only rare complications [19]. Mortality is lessened over the standard scalpel UPPP, at least in part, from

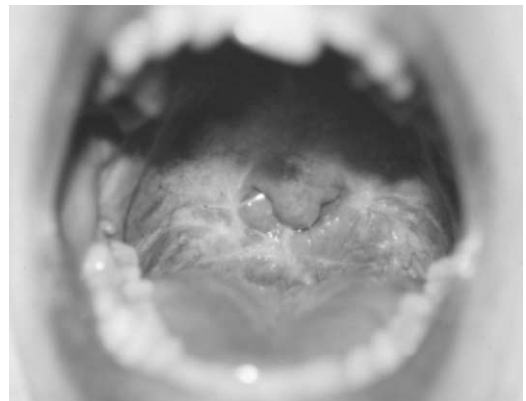

Fig. 8. Scarring of the palate to the pharyngeal wall following LAUP. Caused by inadvertent thermal damage to the wall by the backstop with adhesion to the palate.

the ability to perform these procedures under local anesthesia or I.V. sedation, thereby obviating the need for much higher-risk general anesthesia.

Discussion

Despite its detractors, the LAUP procedure, with nearly 10 years of clinical use, is now an accepted method of effectively treating socially unacceptable snoring. Even those surgeons who made the leap to radiofrequency somnoplasty because of its shorter recovery time and decreased postoperative pain are returning to the LAUP for patients with thick palates or those who fail the somnoplasty procedure. Although many of the studies done to demonstrate the LAUP's effectiveness for simple snoring have been subjective in nature, usually involving patient or sleep partner questionnaires, it is clear that this procedure is clinically effective at diminishing snoring to a socially acceptable level in the majority of patients, approximating the same 90–95% success rates seen with scalpel UPPP [20–22]. Long-term success rates drop to 50–70% caused, no doubt, by some relapse of the soft tissues as well as weight gain and behavioral changes [23,24]. Nevertheless, 92% of our patients questioned at 1 year postoperatively were happy with the results of their surgery and would do the procedure again if the need arose [25].

Several objective studies have also shown that the LAUP does indeed decrease snoring to low and acceptable levels [26–28]. Just as importantly, Armstrong et al, in a subjective study, showed that there was a significant improvement in the quality of life after the LAUP in habitually snoring patients and their sleep partners, as measured by marital happiness, physical health, psychological health, and social relationships [29]. When comparing UPPP with LAUP for snoring diminishment, Osman et al showed no significant difference between the two in improvement of snoring index (SI) [28]. Although all of these studies examined the patients after the original standard LAUP, it would seem reasonable to assume that the results after LA-UPPP would be at least as good if not better. In fact, it is the feeling of many surgeons, including this author, that the LA-UPPP carries with it the potential for only minimally added morbidity over the LAUP but results in more predictable airway opening and long-term results and should therefore be used routinely in place of the standard LAUP procedure. Further research is needed to prove this hypothesis.

The use of the LAUP and LA-UPPP for the management of obstructive sleep apnea is consid-

erably more controversial, and objective data has only recently been forthcoming. Reda et al have shown that habitual snoring patients have statistically long soft palates, long wide uvulas, and narrowed oropharyngeal isthmuses [30]. Though there are multiple possible anatomical sources for the vibratory etiology of snoring, it would stand to reason that excisional laser procedures of the soft palate, a common source of snoring, would result in shorter and tighter soft palates and diminishment of the snoring. And though Reda et al showed that the LAUP did indeed do this, it also interestingly further reduced the already narrow space between the posterior tonsillar pillars [30]. In fact, one study surprisingly demonstrated a 4% overall decrease in airway volume within the first 72 hours after LAUP. Conversely, other studies have shown an increase in the cross-sectional size of the velopharyngeal area and anteroposterior diameter [31].

Although not an issue for snoring, where subjective improvement is an adequate measure of success, it is the basic concerns over the unpredictable nature of these procedures that have brought the LAUP and LA-UPPP into question as viable and safe treatment alternatives for sleep apnea. A review of the literature reveals a few objective polysomnographic-based studies that bear out this lack of certainty and predictability. Lauretano et al found the LAUP to be effective for snoring yet ineffective for all degrees of sleep apnea. Ryan and Love concluded in their studies that the LAUP is highly variable and unpredictable for sleep apnea, with approximately 36% of patients improving (>50% decrease in the Respiratory Disturbance Index or RDI), 34% showing little change, and 30% actually worsened after surgery [27]. Interestingly, they found no change in the SI in these patients either, yet they did find a significant increase in quality of life indicators in all domains, along with a decrease in sleepiness. They concluded from this data that there is little correlation between subjective and objective improvement in sleep apnea following surgery [27].

Conversely, several equally scientific, polysomnographic-based studies showed the LAUP to indeed be both a safe and effective tool in the management of obstructive sleep apnea. Walker and Grigg-Damberger, Walker and Garrity et al, Mickelson and Ahuja, and Pribitkin et al have all published data indicating that the LAUP is at least as good as UPPP for treating obstructive sleep apnea [32–35]. Results are generally in the range of 50–70% decrease of the RDI in most patients, again approximating the results seen with scalpel UPPP. Some limit this to mild apnea with an RDI of less than 30/hr [33], whereas others

demonstrated effectiveness even with severe obstructive sleep apnea [35].

Summary

The LAUP and the LA-UPPP appear by most measures to be safe and reliable tools in the management of socially unacceptable snoring and mild sleep apnea, although much of the documentation to this effect is subjective. When used for moderate to severe sleep apnea, there are still considerable differences of opinion in the literature as to their effectiveness, although they appear in most of the literature to be more or less equivalent to the scalpel UPPP, with less morbidity. Most surgeons would consider the LAUP and LA-UPPP, just as they would (and should) UPPP, to be one useful facet of a more complicated and complete surgical treatment protocol for moderate to severe sleep apnea.

References

- [1] Kamami YV. Laser CO₂ for snoring: preliminary results. *Acta Otorhinolaryngol Belg* 1990;44:451–6.
- [2] Krespi YP, Keider A. Laser-assisted Uvulopalatoplasty for the treatment of snoring. *Op Tech Otolaryngol Head Neck Surg* 1994;5:228–34.
- [3] Krespi YP, Ling EH. Laser-assisted serial tonsillectomy. *J Otolaryngol* 1994;23:325–7.
- [4] Kamami YV. Ambulatory treatment of sleep apnea syndrome with CO₂ laser—a review of 53 cases. *J Fr Otorhinolaryngol* 1994;43(3):183–8.
- [5] Carenfelt C. Laser uvulopalatoplasty in treatment of habitual snoring. *Ann Otol Rhinol Laryngol* 1991;100:451–4.
- [6] Practice parameters for the use of laser-assisted uvulopalatoplasty. Standards of Practice Committee of the American Sleep Disorders Association. *Sleep* 1994; 17:744–8.
- [7] Crumley RL, Stein M, et al. Determination of obstructive site in obstructive sleep apnea. *Laryngoscope* 1987;97:301–12.
- [8] Strauss RA. Upper airway examination and nasopharyngoscopy. *J Oral Maxillofac Surg* 1996;54(8): 12–3.
- [9] Coppola MP, Lawee MS. Management of obstructive sleep apnea syndrome in the home. The role of portable sleep apnea recording. *Chest* 1993;104:19–25.
- [10] Emsellem HA, Corson WA, et al. Verification of sleep apnea using a portable sleep apnea screening device. *So Med J* 1990;83(7):748–52.
- [11] Redline S, Tosteson T, et al. Measurement of sleep related breathing disturbances in epidemiologic studies. *Chest* 1991;100:1281–86.
- [12] Strauss RA. Lasers in oral and maxillofacial surgery. *Dent Clin NA* 2000;44(4):851–73.
- [13] Croft CB, Golding-Wood DG. Uses and complications of uvulopalatopharyngoplasty. *J Laryngol Otol* 1990; 104:871–5.
- [14] Fairbanks DN. Uvulopalatopharyngoplasty complications and avoidance strategies. *Otolaryngol Head Neck Surg* 1990;102:239–45.
- [15] Haavisto L, Suopaa J. Complications of uvulopalatopharyngoplasty. *Clin Otolaryngol* 1994;18:243–7.
- [16] Terris DJ, Clark AA, et al. Characterization of post-operative edema following laser-assisted uvulopalatoplasty using MRI and polysomnography: implications for the outpatient treatment of obstructive sleep apnea syndrome. *Laryngoscope* 1996;106:124–8.
- [17] Walker RP, Grigg-Damberger M, et al. Uvulopalatopharyngoplasty versus laser-assisted uvulopalatoplasty for the treatment of obstructive sleep apnea. *Laryngoscope* 1997;107:76–82.
- [18] Pinczower E. Globus sensation after laser-assisted uvulopalatoplasty. *Am J Otolaryngol* 1998;19(2):107–8.
- [19] Remacle M, Betsch C, et al. A new technique for laser-assisted uvulopalatoplasty: decision-tree analysis and results. *Laryngoscope* 1999;109:763–8.
- [20] Neruntarat C. Laser assisted uvulopalatoplasty: short-term results and long-term results. *Otolaryngol Head Neck Surg* 2001;124:90–3.
- [21] Vukovic L, Hutchings J. Patient evaluation of laser-assisted uvulopalatoplasty. *J Otolaryngol* 1996;25(6): 404–7.
- [22] Wareing M, Callanan V, et al. Laser-assisted uvulopalatoplasty: six and eighteen month results. *J Laryngol Otol* 1998;112:639–41.
- [23] Janson C, Gislason T, et al. Long-term follow-up of patient with obstructive sleep apnea treated with uvulopalatoplasty. *Arch Otolaryngol Head Neck Surg* 1997; 123:257–62.
- [24] Katsantonis GP, Schweitzer PK, et al. Management of obstructive sleep apnea: comparison of various treatment modalities. *Laryngoscope* 1988;98:304–9.
- [25] Strauss RA. Laser-assisted uvulopalatoplasty and diagnostic nasopharyngoscopy. Data Presented at the International Association of Oral and Maxillofacial Surgeons Biannual Meeting, Budapest Hungary, 1995.
- [26] Kotecha B, Paun S, et al. Laser-assisted uvulopalatoplasty: an objective evaluation of the technique and results. *Clin Otolaryngol* 1998;23:354–9.
- [27] Lauretano A, Khosla R, et al. Efficacy of laser-assisted uvulopalatoplasty. *Lasers Surg Med* 1997;21: 109–16.
- [28] Osman EZ, Osborne JE, et al. Uvulopalatopharyngoplasty versus laser-assisted uvulopalatoplasty for the treatment of snoring: an objective randomized clinical trial. *Clin Otolaryngol* 2000;25:305–10.
- [29] Armstrong MW, Wallace CL, et al. The effect of surgery upon the quality of life in snoring patients and their partners: a between-subjects case-controlled trial. *Clin Otolaryngol* 1999;24:510–22.
- [30] Reda M, Sims A, et al. Morphological assessment of

the soft palate in habitual snoring using image analysis. *Laryngoscope* 1999;109:1655–60.

- [31] Ryan CF, Lowe LL. Unpredictable results of laser-assisted uvulopalatoplasty in the treatment of obstructive sleep apnea. *Thorax* 2000;55:399–404.
- [32] Mickelson SA, Ahuja A. Short-term objective and long-term subjective results of laser-assisted uvulopalatoplasty for obstructive sleep apnea. *Laryngoscope* 1999;109:362–7.
- [33] Pribitkin EA, Schutte SL, et al. Efficacy of laser-assisted uvulopalatoplasty in obstructive sleep apnea. *Otolaryngol Head Neck Surg* 1998;119:643–7.
- [34] Walker RP, Garrity T, et al. Early polysomnographic findings and long-term subjective results in sleep apnea patients treated with laser-assisted uvulopalatoplasty. *Laryngoscope* 1999;109:1438–41.
- [35] Walker RP, Grigg-Damberger MM, et al. Laser-assisted uvulopalatoplasty for the treatment of mild, moderate, and severe obstructive sleep apnea. *Laryngoscope* 1999;109:79–85.