



## Radiofrequency thermal ablation therapy for obstructive sleep apnea

Kasey K. Li, MD, DDS, FACS\*, Nelson Powell, MD, DDS, FACS,  
Robert Riley, MD, DDS, FACS

*Stanford University Sleep Disorders and Research Center, 401 Quarry Road Stanford, CA 94305, USA*

Obstructive sleep apnea (OSA) is associated with repetitive nocturnal airway obstruction, which in turn results in daytime sleepiness and cardiovascular derangements [1]. It is now known that many patients with OSA have a diffused pattern of airway obstruction including nasal, oropharyngeal, and hypopharyngeal regions. Although the surgical management of OSA has achieved excellent cure rate [2,3], many patients decline conventional surgical treatment because of the associated invasiveness and potential risks.

Low wave radiofrequency (RF) energy achieves therapeutic ablation of tissue in a minimally invasive fashion. RF thermal tissue ablation has been previously studied in cardiology for ablation of aberrant pathways in Wolfe-Parkinson-White syndrome [4,5], urology for the treatment of benign prostatic hypertrophy [6], neurosurgery for the treatment of trigeminal neuralgia [7], and oncology for the treatment of liver cancer [8]. In 1995, we began the investigation on the use of RF energy to ablate redundant tissue in the upper airway. From a series of clinical trials, we have demonstrated that RF can be safely and effectively applied to the delicate upper airway tissue to improve OSA. This article outlines the current methods of RF thermal ablation therapy for OSA.

### Biophysics of RF energy

The biophysics of RF thermal tissue ablation result in a predictable tissue injury pattern. RF gen-

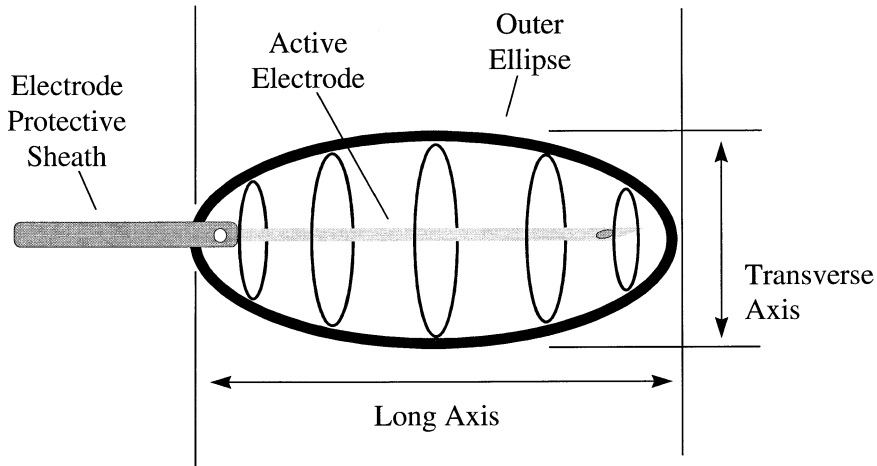
erates frictional heating of the tissue around the electrode caused by ionic agitation; thus, the electrode is not heated and the heat actually emanates from the tissue. Because the energy disbursement pattern is proportional to  $1/\text{radius}^4$ , heat dissipation is limited and excessive tissue injury is minimized. Furthermore, when temperature reaches 90–100°C, char formation on the needle electrode leads to an increase in the impedance and results in disruption of current flow, thus serving as a second layer of protection from excessive tissue injury.

### Tissue reduction by RF thermal ablation

The pattern of the tissue lesion created by RF needle electrode is the shape of an American football (Fig. 1). The length of the lesion is one to two times the length of the active needle portion (eg, 1 cm active needle electrode will create a lesion 1–2 cm in length). The diameter of the lesion is approximately two thirds of the length of the active needle portion. The upper airway tissue response to RF energy was first investigated in the porcine tongue [9]. Twenty-four hours after RF treatment on the tongue, there was evidence of cellular injury with mild interstitial edema and focal hemorrhage, with a margin of hyperemic tissue in the periphery. One week after treatment, there was prominent fibroblastic response, with collagen deposition replacing the injured tissue. Three weeks after treatment, there was a well-formed scar occupying the treated area. Assessment of the tongue volume revealed an initial edematous response that promptly tapered at 24 hours with subsequent tissue reduction 10 days after treatment.

\* Corresponding author. 750 Welch Road, Suite 317, Palo Alto, CA 94304, USA.

E-mail address: Kaseyli@hotmail.com



**General Rule to Predict Maximum Lesion Size:**  
 Long Axis = 2x Length of Active Electrode  
 Transverse Axis = 2/3x Long Axis

Fig. 1. The pattern of radiofrequency (RF) lesion.

A continual reduction of tissue volume was evident through 21 days.

Because the extent of edema is closely correlated with the amount of energy delivered, RF thermal ablation of the redundant upper tissue was designed to be performed as an outpatient procedure, with sequential application of the RF energy with a healing period of 4–6 weeks between treatment session. This approach minimizes excessive postoperative edema and complications. Although increasing the amount of energy delivered during each treatment session can expedite the treatment, the increased risk of airway edema must be anticipated and properly managed.

#### RF thermal ablation of the soft palate

The initial investigation of RF thermal ablation of the soft palate was performed on 22 volunteers in the office setting under local anesthesia [10]. The mean number of treatment sessions was 3.6 per patient. The mean overall total number of joules administered per patient was  $2,377 \pm 869$  J with  $688 \pm 106$  J per treatment session. The mean Epworth Sleepiness Scale (ESS) improved from  $8.5 \pm 4.5$  to  $5.2 \pm 3.3$ . The mean snoring scores by visual analog scale (VAS 0–10) improved from  $8.3 \pm 1.8$  to  $1.9 \pm 1.2$ . There were no major complications such as bleeding, infection, tissue

slough, or speech, taste, and swallowing problems. Soft palate edema occurred in all patients for 1–3 days posttreatment, but all resolved without problems.

#### Long-term follow-up

All twenty-two patients underwent follow-up evaluation [11]. There was a mean weight increase of  $3.1 \pm 7.9$  kg. The mean follow-up period was 14 months (range 12–18 months). There was no adverse effect on speech, swallowing, or taste reported by any of the patients. Thirteen patients (59%) reported continual success without relapse of snoring or daytime sleepiness. Nine patients (41%) reported relapse of snoring (VAS 0–10) from  $2.1 \pm 1.1$  to  $5.7 \pm 2.8$ . This was accompanied by worsening of ESS from  $5.4 \pm 3.2$  to  $7.8 \pm 5.3$ .

Twenty-one patients (95%) were satisfied with the procedure and would go through it all over again. One patient felt that there was insufficient response to the treatment and therefore would not have the procedure again.

Eight of the 9 patients who relapsed consented for retreatment to control snoring further, and they underwent a total of 10 RF treatments, with 6 patients receiving 1 treatment and 2 patients receiving 2 treatments. The mean RF energy delivered per treatment session was  $786 \pm 114$  J. Each patient received a minimum of one or a maximum of three separate

RF ablations per treatment session, with each ablation given at a different site of the palate.

Mild edema was seen in the first three days, which usually resulted in restless sleep on the first post-operative day. There was no report of alteration in daily activities, and normalization of sleep occurred after three days. No mucosal erosion was encountered in any patient and no adverse effect on speech, taste, or swallowing was reported. The pain score was the highest at  $2.7 \pm 1.9$  posttreatment day 1 and decreased to  $0.7 \pm 1.1$  at one week. Oral analgesic was used by three patients and was limited to one tablet of codeine (30 mg) and either acetaminophen or ibuprofen in low doses. The snoring score fell from  $5.8 \pm 2.9$  to  $3.3 \pm 3.1$ , with improved ESS from  $7.8 \pm 5.6$  to  $6.3 \pm 4.6$ .

### RF thermal ablation of the soft palate: current practice

RF thermal ablation of the soft palate is reserved for patients with complaints of snoring or mild sleep-disordered breathing. Patients with OSA should be managed with more aggressive treatments such as uvulopalatopharyngoplasty (UPPP). The primary site of treatment is in the mid portion of the soft palate, in the base of the uvula (Fig. 2). Although the paramedian region can be treated, less RF energy should be delivered because of the increased risk of ulceration as the thickness of the soft palate is reduced in this location.

The procedure starts with local anesthesia using a 30-gauge needle (2–5 ml). A 22-gauge needle electrode (10 mm active length with a 10 mm protective

sheath) is inserted in the midline of the soft palate, with the tip of the needle electrode at the base of the uvula. Typically, 700–750 joules are delivered in the midline. Paramedian RF treatment (250–350 J on each side) can be performed if desired; increasing edema should be expected, however. This technique minimizes the risk of ulceration and discomfort. Prescription analgesics are rarely required. But edema usually occurs and may last a few days. Obviously, the extent of edema is directly correlated with the amount of RF energy delivered.

The procedure is repeated every 4–6 weeks. With proper patient selection, snoring usually can be improved after 3–4 sessions.

### RF thermal ablation of the tongue

Tongue base collapse is a major cause of hypopharyngeal airway obstruction. Therefore, reducing the tongue volume can improve OSA. The initial investigation of RF thermal ablation of the tongue base was performed on 18 volunteers in the office setting under local anesthesia [12].; All of the patients have failed at least UPPP. The mean number of treatment sessions was 5.5 per patient. The mean overall total energy administered per patient was  $8490 \pm 2687$  J with 1543 J per treatment session. The mean respiratory disturbance index (RDI) improved from  $39.5 \pm 32.7$  to  $17.8 \pm 15.6$  events per hour. The lowest oxygen saturation improved from  $81.9 \pm 11.6\%$  to  $88.1 \pm 5.3\%$ . The mean ESS improved from  $10.4 \pm 5.6$  to  $4.1 \pm 3.2$ . Tongue volume was reduced by a mean of 17% based on MRI. Speech and swallowing did not change. Complications

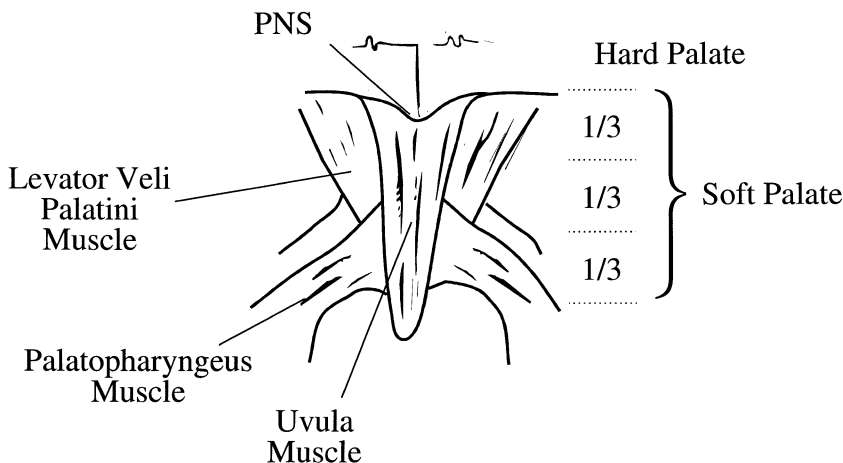


Fig. 2. The soft palate. RF treatment is usually focused on the middle and lower third of the soft palate.

included one case of persistent tongue pain that gradually resolved, one case of ulceration on the surface of the tongue from improper placement of the needle electrode that spontaneously resolved, and one case of tongue base abscess that required incision and drainage.

#### *Long-term follow-up*

Sixteen of the 18 patients underwent follow-up evaluation. There was minimal weight change. The mean follow-up period was 28 months. There was no significant adverse effect on speech or swallowing. The quality of life (SF-36) remained improved over baseline. The RDI relapsed from 17.8 to 28.7 events per hour, however, and the lowest oxygen saturation worsened from 88.3% to 85.8% [13].

#### **RF thermal ablation of the tongue: current practice**

RF thermal ablation of the tongue base is currently reserved for patients with persistent tongue base obstruction after previous OSA surgery such as UPPP and/or genioglossus advancement. It should be emphasized that most patients with OSA have retropalatal obstruction, and this anatomic region should be adequately addressed (usually by uvulopalatoplasty) before RF thermal ablation of the tongue is considered. Furthermore, airway protection with either nasal con-

tinuous positive airway pressure (CPAP) or tracheotomy is mandatory in the postoperative period because RF tongue ablation is usually performed on an outpatient basis and postoperative edema is routinely encountered.

The procedure starts with local anesthesia delivery using a 25- or 27-gauge needle (5–10 ml) in the region of the circumvallate papilla. A 22-gauge needle electrode (10-mm active length with a 10-mm protective sheath) is inserted in the region of the circumvalate papilla (Fig. 3). Typically, 2–3 lesions (750–1000 J per lesion) are delivered. Prescription analgesics as well as antibiotics are routinely used, and the procedure is repeated every 4–6 weeks. Outcomes assessment by polysomnography is usually performed after at least 8000–1000 joules have been administered. Further RF treatment is warranted if there is evidence of improvement.

#### **Summary**

Although the data available for RF thermal ablation for the treatment of sleep-disordered breathing is limited, the available data does support the continual investigation of this novel treatment approach. It should be emphasized, however, that despite the minimally invasive nature of this outpatient treatment technique, severe complications such as airway obstruction or infection with abscess formation can occur. The administration of excessive RF energy in

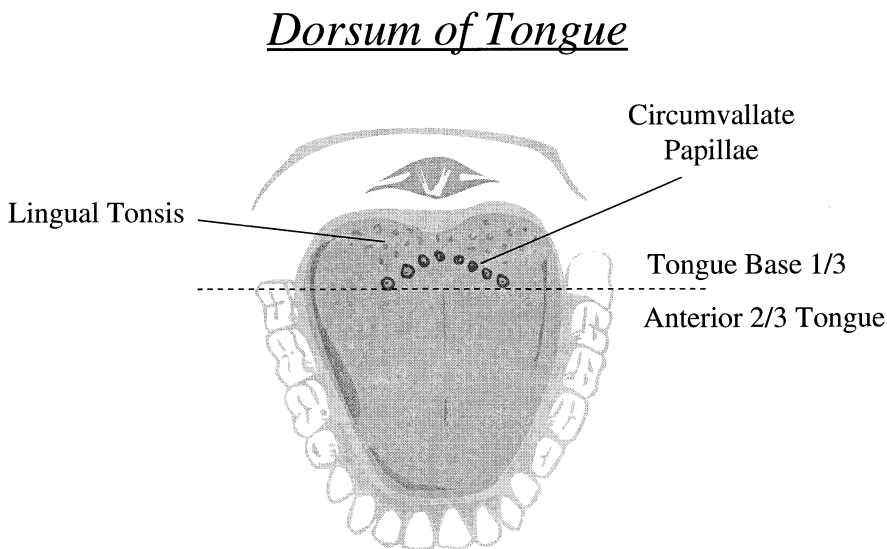


Fig. 3. The tongue base. RF treatment is usually isolated around the circumvallate papilla.

order to limit the number of total treatments or altered treatment location and technique may increase the risk of complication and adverse effects. Caution is advised.

## References

- [1] Indications and standards for use of nasal continuous positive airway pressure (CPAP) in sleep apnea syndromes. *Am J Respir Crit Care Med* 1994;150:1738–45.
- [2] Li KK, Powell NB, Riley RW, Troell RJ, Guilleminault C. Overview of phase I surgery for obstructive sleep apnea syndrome. *ENT J* 1999;78:836–37, 841–45.
- [3] Li KK, Riley RW, Powell NB, Troell RJ, Guilleminault C. Overview of phase II surgery for obstructive sleep apnea syndrome. *ENT J* 1999;78:851, 854–57.
- [4] Jackman WM, Wang XZ, Friday KJ, et al. Catheter ablation of accessory atrioventricular pathways (Wolff-Parkinson-White syndrome) by radiofrequency current. *N Eng J Med* 1991;324:1605–11.
- [5] Calkins H, Sousa J, El-Atassi R, et al. Diagnosis and cure of the Wolff-Parkinson-White syndrome or paroxysmal supraventricular tachycardias during a single electrophysiologic test. *N Eng J Med* 1991;324:1612–8.
- [6] Issa M, Oesterling J. Transurethral needle ablation (TUNA): an overview of radiofrequency thermal therapy for the treatment of benign prostatic hyperplasia. *Curr Opin Urol* 1996;6:20–7.
- [7] Sweet W, Wepsic J. Controlled thermocoagulation of trigeminal ganglion and rootlets for differential destruction of pain fibers: I. Trigeminal neuralgia. *J Neurosurg* 1974;3:143–56.
- [8] LeVeen H, Wapnick S, Piccone V, et al. Tumor eradication by radiofrequency therapy: response in 21 patients. *JAMA* 1976;253:2198–200.
- [9] Powell NB, Riley RW, Troell RJ, et al. Radiofrequency volumetric reduction of the tongue. a porcine pilot study for the treatment of obstructive sleep apnea syndrome. *Chest* 1997;111:1348–55.
- [10] Powell NB, Riley RW, Troell RJ, Li KK, Blumen MB, Guilleminault C. Radiofrequency volumetric tissue reduction of the palate in subjects with sleep-disordered breathing. *Chest* 1998;113:1163–74.
- [11] Li KK, Powell NB, Riley RW, Troell RJ, Guilleminault C. Radiofrequency volumetric reduction of the palate: an extended follow-up study. *Oto Head Neck Surg* 2000;122:410–4.
- [12] Powell NB, Riley RW, Guilleminault C. Radiofrequency tongue base reduction in sleep disordered breathing: A pilot study. *Oto Head Neck Surg* 1999;120:656–64.
- [13] Li KK, Powell NB, Riley RW, Troell RJ. Radiofrequency tongue base reduction: long-term outcomes. *Oto Head Neck Surg* (in press).